CHAPTER 50 Developmental abnormalities of the face, mouth and jaws: cleft lip and palate

Learning objectives

To understand:

- The range and complexity of craniofacial anomalies
- The principles driving interventions for the developing child with a craniofacial anomaly
- In more depth the epidemiology, pathogenesis and management of cleft lip and palate

INTRODUCTION

Congenital abnormalities of the head and neck are complex and often confusing. For these reasons it is helpful to have a classification system that helps to understand the variety of conditions. For any classification system to be useful it should ideally help to explain the aetiology and pathogenesis of the abnormality and to determine treatment. For these multifaceted and multifactorial conditions an ideal classification system is not available. Consequently, there are a number of different systems available: some are purely descriptive (e.g. Tessier's classification of clefts), while others apply only to single conditions, such as the OMENS (O, orbital abnormalities; M, mandibular deformity; E, ear deformity; N, nerve involvement; and S, soft-tissue abnormalities) classification of hemifacial (craniofacial) microsomia, which has utility in instituting treatment protocols.

CLASSIFICATION OF CRANIOFACIAL ABNORMALITIES

van der Meulen and his colleagues proposed a classification system that has significant utility in helping to understand the variety and complexity of craniofacial malformations. This classification considers the embryological development of the craniofacial region. First, in terms of the formation and fusion of the processes (branchial arches): the failure of the fusion

TABLE 50.1 Types of developmental abnormalities of the face, mouth and jaws.

Type	Examples
Cerebrocranial dysplasias	Anencephaly, microcephaly
Cerebrofacial dysplasias	Rhinencephalic and oculo-orbital dysplasias
Craniofacial dysplasias with clefting	Lateronasomaxillary, medionasomaxillary, intermaxillary, maxillomandibular clefting
Craniofacial dysplasias with dysostosis	Sphenoidal, sphenoidal frontal, frontal, frontofrontal, frontonasoethmoidal, internasal, nasal, premaxillomaxillary, nasomaxillary, maxillozygomatic, zygomatic, zygoauromandibular, temporoauromandibular, mandibular, intermandibular
Craniofacial dysplasias with synostosis	• Craniosynostosis: lambdoid and sagittal • Craniofaciosynostosis: metopic, coronal, bicoronal • Faciosynostosis: vomeropremaxillary (Binder syndrome)
Craniofacial dysplasias with dysostosis and synostosis	Crouzon, Apert and Pfeiffer syndromes
Craniofacial dysplasias with dyschondrosis	Achondroplasia

After van der Meulen JC, Mazzola R, Vermey-Keers C *et al.* A morphogenetic classification of craniofacial malformations. *Plast Reconstr Surg* 1983; **71**(4): 560–72.

Paul Tessier, 1917–2008, French maxillofacial surgeon, considered the 'father of modern craniofacial surgery'.
Jacques C H van der Meulen, 1929–2017, Professor in Plastic and Reconstructive Surgery, Erasmus University, Rotterdam, The Netherlands.
Karl Heinz Binder, 1923–2016, German dentist, documented the facial features of three children with the condition that now bears his name.
Louis Edouard Octave Crouzon, 1874–1938, neurologist, Paris, France, described this syndrome in 1912.
Eugene Apert, 1868–1940, physician, L'Hôpital des Infants Malades, Paris, France, described this syndrome in 1906.
Rudolf Arthur Pfeiffer, 1931–2012, geneticist, Münster, Germany, described this syndrome in 1964.

of these processes leads to clefting disorders, for example the failure of fusion between the frontonasal process and the maxillary process results in a cleft lip, either unilaterally or bilaterally. Second, in the formation of bone and cartilage; if this is abnormal it is termed dysostosis or dyschondrosis. Third, the formation and growth at the sutures between the various bones of the craniofacial skeleton: premature fusion leads to synostosis. Superimposed on this concept is the consideration of the development of the central nervous system; this leads to a number of types of abnormality, as outlined in ***Table 50.1***.

In addition, and in common with all classification systems, there is another large group of conditions that do not sit within the system outlined above and also listed in ***Table 50.1***.

EPIDEMIOLOGY

The incidence of congenital craniofacial anomalies varies in different parts of the world and is often not easy to quantify. ***Table 50.2*** outlines the various incidences of the more common craniofacial abnormalities.

TABLE 50.2 Approximate incidence data from multiple sources.

Condition	Incidence
Apert syndrome	1 in 100 000
Pfeiffer syndrome	1 in 100 000
Crouzon syndrome	1 in 62 500
Treacher Collins syndrome	1 in 50 000
Unicoronal synostosis	1 in 10 000
Metopic synostosis	1 in 7000
Sagittal synostosis	1 in 5000
Hemifacial microsomia	1 in 3500
Neurofibromatosis	1 in 2600
Cleft lip and palate	1 in 600

DIAGNOSIS

The diagnosis of the craniofacial anomalies has, in recent years, undergone a massive change on two fronts: first, advances in ultrasonography have increased the rate of prenatal diagnosis and impacted management significantly; second, the rapid expansion in genetic understanding has led to many more mutations being linked to particular phenotypes. Despite these advances the diagnosis of the majority of these conditions remains clinical.

MANAGEMENT

In considering the management of this vast range of heterogeneous congenital abnormalities it is very difficult to generalise about management protocols. The vast majority of management is delivered by multidisciplinary teams (MDTs) within specialist centres.

Prenatal management

There have been a few reported cases of prenatal surgery when a diagnosis was made or suspected prenatally. However, these procedures remain at present experimental; in general, the options open are for termination or best supportive care in preparation for the birth. This can often provide the parents with a period of time to adjust to the impending birth of a child with additional demands and needs. The opportunity to meet parents, adults and children who have experienced the same condition is often very valuable. Termination and its therapeutic uses is obviously a contentious and very personal issue. However, some parents may request this for very treatable conditions (e.g. isolated cleft lip); in these circumstances, the local ethics board must be involved and ultimately on occasions the advice of the courts must also be sought.

Neonatal management

In the neonatal period management is aimed at addressing the urgent issues relating to the airway, breathing, eye protection and establishing feeding.

In many of the craniofacial conditions the airway can be affected and may be fully or partially obstructed. This may be because of a retropositioned hypoplastic maxilla – the tongue falling back to close off the upper airway; this is often compounded by a hypoplastic mandible. The trachea itself may also be abnormal and tracheomalacia can lead to respiratory problems. Neonates are obligate nasal breathers and some forms of nasal obstruction can precipitate airway symptoms. In the most severe cases intubation is not possible as a result of the abnormal anatomy and a tracheostomy may be necessary. In emergency situations it may be helpful to nurse the baby prone, allowing the tongue to fall forwards.

In some cases, particularly the syndromic craniosynostoses such as Apert syndrome, Pfeiffer syndrome or Crouzon syndrome, the combination of midface retrusion and brachycephalic forehead shape can lead to severe exorbitism. In the worst cases this can cause ocular dislocation with the eyelids closing behind the globe. In severe exorbitism the eyelids do not close adequately to moisturise and protect the cornea; without intervention this may lead to irreversible corneal damage.

In neonates with airway embarrassment, even without anatomical abnormalities, the effort of breathing can be exhausting and this can significantly compromise the ability to feed. Structural anomalies can also affect the ability to feed; expert input from a specialist feeding nurse is often helpful. The use of specialised teats may be helpful but in some cases naso- or orogastric feeding may be necessary.

Management in infancy (0–12 months)

At this age treatment falls into two categories: that directed at major functional issues as for neonatal care and that directed at skull surgery in cases of craniosynostosis.

Edward Treacher Collins, 1862–1932, ophthalmic surgeon, Royal London Ophthalmic Hospital and Charing Cross Hospital, London, UK, described this syndrome in 1900.

In the older child the indications for surgery remain the same; however, there is the possibility of surgery to advance the mandible in the severely retrognathic patient. This can be used to obviate the need for a tracheostomy or to allow for early decannulation. The most effective technique is distraction osteogenesis (or distraction histogenesis), which utilises the same basic principles as in limb lengthening. The bone is cut and a device placed across the osteotomy site; after a short latent period the bone ends are gradually separated, distracting the callus. In the mandible, unlike the long bones, it is not necessary to limit the bone cut to the cortex (corticotomy) and a complete osteotomy is used. The technique allows for a lengthening of approximately 1 mm/day, after which there is a retention period to allow for consolidation of the callus.

Craniosynostosis results in premature fusion of one or more of the skull sutures. The conditions may be isolated or part of a syndrome. This can result in abnormalities of both the skull and, particularly in syndromic cases, the facial skeleton. In 10–20% of single-suture cases and a higher proportion of syndromic multisuture cases the infants develop raised intracranial pressure, which presents as episodes of distress, listlessness and disturbed sleep. This may be associated with papilloedema and, untreated, can lead to visual failure. The diagnosis is confirmed with intracranial pressure monitoring.

Some congenital lesions may obstruct the vision of one or both eyes and this type of problem needs to be addressed to minimise the chances of amblyopia developing. An example of this would be the development of a large true haemangioma of the eyelids threatening to obscure the child's vision out of one eye.

Management in early childhood (1–12 years)

In early childhood management should be aimed at dealing with functional problems – airway obstruction, speech and feeding issues – but there is an increasing imperative for surgery to address the appearance of the child. There is no doubt that visible differences can affect a child's development, both socially and emotionally; however, there is a significant role for psychological and emotional support for the whole family and in some cases for the school community to help the child, family and school understand and deal with the additional pressures that visible difference makes. Surgery can make a significant difference for some patients, but for many surgery should be delayed as long as possible for an optimal outcome in the long term.

In the older child airway issues can become a problem and their identification is more difficult. The usual presentation is of sleep apnoea, which often has an insidious onset; the history should be actively sought as parents may be accustomed to noisy snoring and daytime tiredness in the child and may not consider it abnormal. Initial investigation is with a home overnight oxygen saturation monitor, which, if abnormal, should trigger a comprehensive sleep study. The management of obstructive sleep apnoea includes the use of tonsillectomy/adenoidectomy, midface advancement and mandibular distraction as well as a variety of ventilator support devices.

Management in late childhood to maturity

Airway and other functional issues are usually stabilised by this time and interventions are aimed at optimising the overall appearance. The transition from primary school to secondary school is often a period of distress for patients with visible differences and their families. If there are pressing psychological reasons corrective surgery can be offered, although this is usually best postponed until growth is complete. In general, a comprehensive integrated corrective plan should be developed within the MDT. This would usually address the skeletal and dental abnormalities first and then address the soft tissues. The majority of the major craniofacial abnormalities should be managed by a formal MDT.

CLEFT LIP AND PALATE

Introduction

Cleft lip and/or palate is the most common congenital abnormality affecting the orofacial region. These conditions most commonly occur as isolated deformities but can also be associated with other medical conditions, e.g. congenital heart disease. They are also an associated feature in over 300 recognised syndromes. All children born with a cleft are screened for other congenital abnormalities. Where the cleft is thought to be associated with a syndrome any appropriate further investigations, including genetic counselling, will be organised.

Incidence

The incidence of cleft lip and/or palate is around 1:600 live births. There are geographical and ethnic variations, with a higher incidence among the South East Asian and Native American populations than elsewhere in the world. The accuracy of these figures may be questionable owing to a variance in reporting and healthcare infrastructure.

The typical distribution of cleft types is:

- cleft lip alone: 15% (***Figure 50.1a,b***);
- cleft lip and palate: 45%;
- isolated cleft palate: 40% (***Figure 50.1c***).

Classification of cleft

Cleft lip and/or palate presents in a heterogeneous manner. In simple terms these conditions can be divided into two clinical types (phenotypes):

1. isolated cleft palate;
2. cleft lip with or without involvement of the alveolus (tooth-bearing portion of the jaw) or palate.

Within these broad classifications a variety of combinations of cleft type can exist. These all aim to define the extent and laterality of the cleft (left/right/bilateral) (***Figure 50.2***). This information is both diagnostic and, increasingly, of prognostic value. Many have argued for a single classification system to be

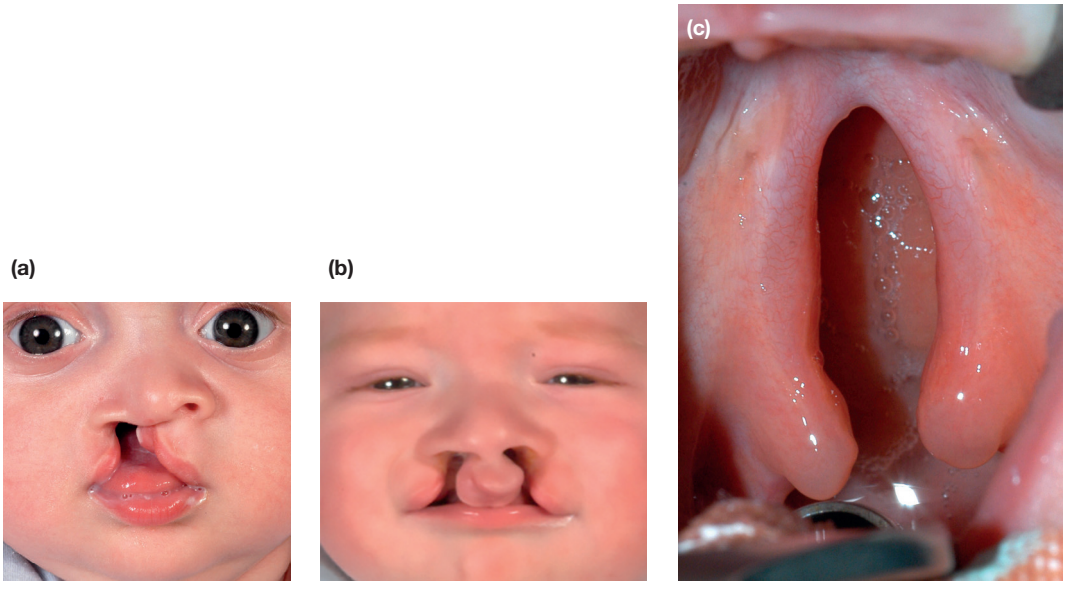

Figure 50.1 (a) Unilateral cleft lip. **(b)** Bilateral cleft lip. **(c)** Isolated cleft palate.

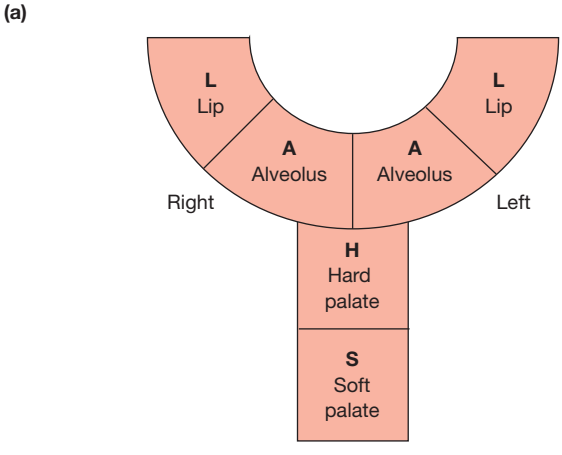

(b)

Class	Description
I	Soft palate only
II	Hard and soft palate to the incisive foramen
III	Complete unilateral of soft, hard, lip and alveolar ridge
IV	Complete bilateral of soft, hard and/or lip and alveolar ridge

Figure 50.2 (a) The LAHSHAL code. **(b)** The Veau classification system.

adopted: even when the same system is being used, clinicians may interpret the findings inconsistently.

In the UK, national audit data are collected for outcomes in unilateral cleft lip and palate (UCLP), thus allowing intercentre comparison. Cleft lip and/or palate is more common in males, whereas isolated cleft palate is more common in females. In UCLP the condition affects the left side in 60% of cases.

Summary box 50.1

Overview of cleft lip and palate

- Cleft lip and/or palate has two main phenotypes
- Cleft palate is more common in females and cleft lip and/or palate is more common in males
- The incidence/prevalence demonstrates geographical variation
- There are simple classification systems that describe phenotype

Aetiology

Non-syndromic cleft lip and/or palate may present as new diagnosis within a family or with a clear family history. A family history of cleft lip and palate in which a first-degree relative is affected increases the risk of subsequent cleft cases in the family, supporting the theory that there are underlying genetic mutations contributing to the aetiology. Isolated cleft palate is more commonly associated with a syndrome than cleft lip and palate and isolated cleft lip. Over 150 named syndromes are associated with cleft lip and palate, although Stickler (ophthalmic and musculoskeletal abnormalities), DiGeorge (cardiac/thymic anomalies), Down, Apert and Treacher Collins syndromes are most frequently encountered.

Victor Veau, 1871–1949, French surgeon and author of several books on cleft lip and cleft palate surgery.
Gunnar B Stickler, 1925–2010, born in Germany, Chair of Section of Paediatrics and later Paediatric Cardiology, The Mayo Clinic, Rochester, MN, USA.
Angelo Mario DiGeorge, 1921–2009, Italian American physician and pediatric endocrinologist.
John Langdon Haydon Down (sometimes given as Haydon-Down), 1828–1896, physician, The London Hospital, London, and Superintendent, Earlswood Asylum for Idiots, Surrey, UK, described this syndrome in 1866.

Various environmental factors have been implicated in the aetiology of cleft lip and/or palate, including maternal epilepsy (and associated medication) and drugs (e.g. steroids, diazepam, sodium valproate and phenytoin). The role of antenatal folic acid supplements in preventing cleft lip and/or palate remains equivocal.

Pierre Robin sequence is a condition worth considering in specific terms. This sequence comprises isolated cleft palate, retrognathia and a posteriorly displaced tongue (glossoptosis), which is associated with early airway and feeding difficulties.

Although airway obstruction does not commonly occur in babies with a non-syndromic cleft lip and/or palate, in babies with an airway obstruction, e.g. Pierre Robin sequence, hypoxic episodes during sleep and feeding can be life-threatening. Intermittent airway obstruction is more frequent and is managed conservatively. In more severe cases the children will often require adjunctive support for their airway compromise such as supplemental oxygen, nasopharyngeal airway and even tracheostomy. More controversially, surgical adhesion of the tongue to the lower lip (labioglossopexy) in the first few days after birth is an alternative but less commonly practised method of management. Mandibular distraction surgery has advocates but numerous attempts at developing a consensus view in support of this procedure for airway compromise in cleft have been unsuccessful.

Summary box 50.2

Aetiology of cleft lip and palate

- The cause of cleft lip and/or palate is multifactorial
- Most cases occur without a clear family history or known risk factors
- Clefts can be associated with many craniofacial/medical syndromes

Cleft lip and/or palate: embryology and pathogenesis

Embryologically, the lip and palate are derived from facial prominences/processes.

1. The lip/nose complex is derived from a mixture of the median nasal process and the maxillary processes.
2. The primary palate is derived from the median nasal process and consists of all anatomical structures anterior to the incisive foramen, namely the alveolus and philtral portion of the upper lip. The remainder of the lip is derived from the maxillary processes.
3. The secondary palate is derived from the maxillary processes and is defined as the remainder of the palate behind the incisive foramen, which is divided into the hard palate and, more posteriorly, the soft palate. Cleft palate results in failure of fusion or descent of the two palatal shelves. This failure to descend, fuse or remain fused can result in a cleft affecting any part of the palate.

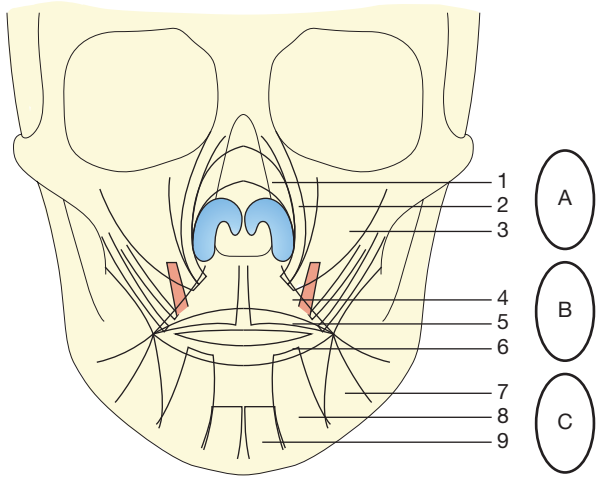

Figure 50.3 The muscle chains of the face: frontal view. The nasal cartilages are represented in blue. A, nasolabial (muscles 1–3); B, bilabial (muscles 4–6); C, labiomental (muscles 7–9); 1, transverse nasalis; 2, levator labii superioris alaeque nasi; 3, levator labii superioris; 4, orbicularis oris (oblique head) – upper lip; 5, orbicularis oris (horizontal head) – upper lip; 6, orbicularis oris – lower lip; 7, depressor anguli oris; 8, depressor labii inferioris; 9, mentalis.

Clinical anatomy

The muscle chains of the face are shown in ***Figure 50.3***. Their disruption in unilateral cleft lip is shown in ***Figure 50.4***.

Summary box 50.3

Embryology and pathogenesis of cleft lip and/or palate

- Clefts occur at the points of fusion of facial processes
- Normal anatomical structures are displaced and disrupted
- Abnormal muscle insertion results in aesthetic and functional sequelae

Cleft lip

The abnormalities in cleft lip are the direct consequence of disruption of the muscles of the upper lip and nasolabial region. The muscle continuity is disrupted, leading to the cleft lip and also abnormal insertions of the muscle at the cleft edge. The effect of this can be seen on the nasal septum and the nose itself.

Unilateral cleft lip

In the unilateral cleft lip, the muscle rings are disrupted on one side, resulting in an asymmetric upper lip and/or nose. This involves the external nasal cartilages, nasal septum and anterior maxilla (premaxilla). This influences the mucocutaneous tissues, causing a displacement of nasal skin onto the lip and a retraction of labial skin, as well as changes to the vermilion and lip mucosa. All these changes need to be considered in planning the surgical repair of the unilateral cleft lip.

Pierre Robin, 1867–1950, Professor, The French School of Dentistry, Paris, France, described this syndrome in 1929.

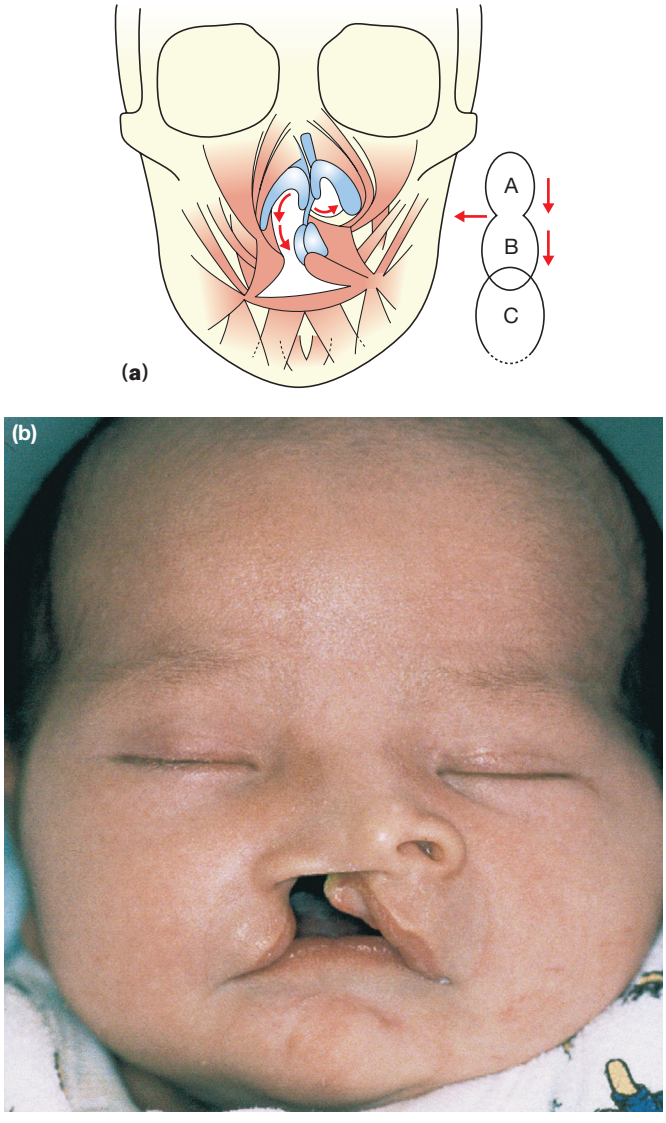

Figure 50.4 (a) Schematic representation of disruption of the nasolabial and bilabial muscle chains in unilateral (right) cleft lip. A, nasolabial; B, bilabial; C, labiomental. (b) Unilateral cleft lip before muscular reconstruction (courtesy of William P Smith).

Bilateral cleft lip

In the bilateral cleft lip the disruption is greater but often symmetrical. Muscular continuity is disrupted bilaterally, producing a flaring of the nose (caused by a lack of nasolabial muscle continuity), a protrusive premaxilla and an area of skin in front of the premaxilla devoid of muscle, known as the prolabium. As in the unilateral cleft lip, the muscular, cartilaginous and skeletal deformities influence the mucocutaneous tissues, which must be respected in planning the repair of the bilateral cleft lip.

Cleft palate

Embryologically, the primary palate consists of all anatomical structures anterior to the incisive foramen, namely the alveolus and upper lip. The secondary palate is defined as the remainder of the palate behind the incisive foramen, divided into the hard palate and, more posteriorly, the soft palate.

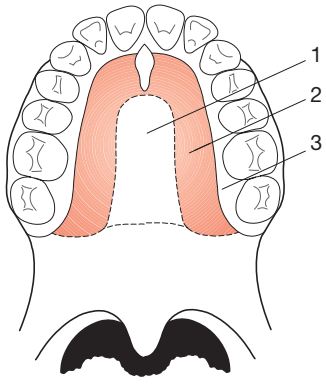

Figure 50.5 The three mucosal zones of the hard palate. 1, palatal fibromucosa; 2, maxillary fibromucosa; 3, gingival fibromucosa.

Cleft palate results in failure of fusion of the two palatine shelves. This failure may be confined to the soft palate alone or involve both hard and soft palate. When the cleft of the hard palate remains attached to the nasal septum and vomer, the cleft is termed incomplete. When the nasal septum and vomer are completely separated from the palatine processes, the cleft palate is termed complete.

Soft palate

In the non-cleft soft palate, closure of the velopharynx, which is essential for normal speech development, is achieved by elevation of the soft palate. Although this is achieved by coordinated muscular activity, it is the levator veli palatini that is the key muscle in achieving this. In general, the muscle fibres of the soft palate are orientated transversely with no significant attachment to the hard palate. In a cleft palate the muscle fibres are orientated in an anteroposterior direction, inserting into the posterior edge of the hard palate.

Hard palate

The hard palate can be divided into three anatomical and physiological zones (*Figure 50.5*). The central palatal fibromucosa is very thin and lies directly below the floor of nose. The maxillary fibromucosa is thick and contains the greater palatine neurovascular bundle. The gingival fibromucosa lies more lateral and adjacent to the teeth.

In performing surgical closure of a cleft palate, the changes associated with the cleft must be understood to obtain an anatomical and functional repair. In complete cleft palate the median part of the palatal vault is absent and the palatal fibromucosa is reduced in size. The maxillary and gingival fibromucosa are not modified in thickness, width or position.

The cleft multidisciplinary team and primary management

The cleft team

Modern cleft services rely on well-coordinated patient pathways. The pathways and protocols may vary from country to country but the aims of treatment are consistent. Care is

provided from diagnosis onwards to ensure that every patient with cleft lip and/or palate has appropriate access to the correct clinician and care at the optimal time. In the UK, most children with a cleft involving the lip are diagnosed antenatally. Scanning protocols now include an 'anomaly scan' at around 20 weeks. Isolated cleft palate cannot be diagnosed antenatally using routine scanning techniques. Some researchers have suggested that Doppler studies may help in diagnosing isolated cleft palate. When an antenatal diagnosis is confirmed, referral to a cleft team is appropriate. Clinical nurse specialist involvement would commence from this point onwards.

The cleft MDT therefore has a range of clinical expertise and specialisms within it. These are:

- **Cleft coordinator/administrator**. This is vital to ensure that patients and families have clinical episodes organised as per the protocol of the service. Responsive administrative support is vital for patients, families and clinicians.
- **Clinical nurse specialist** (CNS). The role of the CNS is central to the safe and effective delivery of cleft care. These clinicians will, in most cases, be the first clinical contact with the team. The CNS will assess the child and provide initial support to the family. Assessment of feeding, airway and general well-being is carried out. The role of the CNS is vital in ensuring that each child is optimally prepared for surgery.
- **Paediatrician**. Most children who have a cleft will be otherwise well. In some cases there may be associated or coexisting medical problems, e.g. cardiac or respiratory. These will require appropriate specialist input and perhaps coordination of care by a paediatrician.
- **Speech and language therapist** (SLT). The input of an SLT is vital where palatal involvement exists in the cleft type. Assessment and therapy are provided where required. Outcome measurements and diagnosis of palatal dysfunction are key elements of the SLT's role in cleft care.
- **Ear–nose–throat (ENT)/audiology**. Regular hearing tests and effective intervention for hearing loss are vital in ensuring speech development. This is a key part of early cleft care.
- **Paediatric dentist**. Traditionally dental/oral health has been poor for this patient group. A greater emphasis on disease prevention has resulted in much improved dental outcomes. A key part of early health care would involve a paediatric dentist.
- **Orthodontist**. The role of the orthodontist varies in different services. Some services will have early orthodontic intervention to mould the anterior cleft presurgically. This is not undertaken in many countries, e.g. the UK. The orthodontist, therefore, becomes a key figure at around 7 years of age as the child enters the early 'mixed dentition' phase. Assessment and preparation for alveolar bone grafting (ABG) as well as definitive orthodontic alignment are undertaken where required. The orthodontist is a key member of the team delivering orthognathic (jaw alignment) surgery at the point of skeletal maturity if required.
- **Clinical psychologist**. These clinicians are involved throughout the clinical pathway, providing support to patients, families and team members. Key outcomes in relation to quality of life are assessed by these clinicians.
- **Cleft surgeon**. The cleft surgeon's role is to provide assessment and intervention to patients. The main aim of cleft surgery is to correct the underlying anatomical abnormalities that can lead to issues with appearance and function. Optimal clinical outcomes can be achieved for most patients with limited surgical intervention. One to three operative interventions (depending on the type of cleft) in childhood are all that would be planned as part of a cleft pathway/protocol. Outcomes of surgery/cleft care are audited annually in most countries.

Immediate/neonatal care

Feeding

Babies born with a cleft involving the palate will feed well and thrive, provided that they receive the appropriate CNS input. The feeding aids for a child with a cleft palate aim to improve the efficiency of delivery of milk, reducing the effort of feeding. Expressed breast milk is best. A range of modified bottles and teats are available. Soft bottles allow the parents to do much of the work of milk delivery for the child by synchronising their 'squeeze' to the baby's 'suck'. Feeding plates, constructed from a dental impression of the upper jaw, were used in the past in the UK and may still be used in other parts of the world.

In some units, babies are provided with an active plate that aims not only to improve feeding but also to reduce the width of the cleft and improve the shape of the nose prior to surgery – nasoalveolar moulding (NAM). The evidence in the literature of long-term benefit using such a regime is conflicting.

Summary box 50.4

Immediate/neonatal care for a patient with a cleft and/or palate

- Babies born with a cleft may have issues with feeding and airway
- A team of clinicians is required to meet all the needs of a child with a cleft
- Most of the care delivered to a child with a cleft lip and/or palate is non-surgical in the initial phase

PRINCIPLES OF CLEFT SURGERY

The ultimate aim in cleft lip and palate management is to facilitate normal development and well-being. In seeking this, surgical repair is aimed at producing normal anatomy in the lip, nose and palate. Essentially, oral and dental health should also be optimised in the management. Key outcomes measured include speech, facial growth, general well-being and dental health.

With the exception of rare conditions such as holoprosencephaly, there is no true hypoplasia of the tissues involved

Christian Johann Doppler, 1803–1853, Professor of Experimental Physics, Vienna, Austria, enunciated the 'Doppler principle' in 1842.

Figure 50.6 Postoperative unilateral cleft lip repair.

Figure 50.7 Postoperative bilateral cleft lip repair.

on either side of the cleft. There is, however, displacement, deformation and underdevelopment of the muscles and facial skeleton. Emphasis is placed on muscular reconstruction of the lip, nose and face as well as muscles of the soft palate.

Normal or near-normal anatomy promotes normal function, thereby encouraging normal growth and development of lip, nose, palate and facial skeleton. An in-depth understanding of the anatomy of the cleft is invaluable if the surgeon is to achieve normal, or near-normal, anatomical reconstruction.

Surgical techniques

Much debate and variation exist across the world in the timing and techniques employed in cleft repair. All have the common aims stated above. Restoration of form and function can be achieved using many of these protocols, but the following protocol is that which is used in the UK and was popularised in Norway.

- Cleft lip/nose and anterior palate repair is performed between 3 and 6 months of age (***Figures 50.6 and 50.7***).
- The anterior palate closure is achieved by using a single-layer mucosal flap from the vomer. The lip is closed using a variety of described techniques but most surgeons believe that the muscle repair is more important than the skin incision, hence the variation.

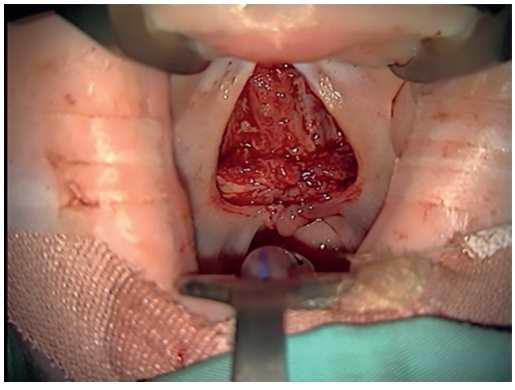

Figure 50.8 Dissection of the levator muscles.

- Definitive cleft palate repair is carried out between 6 and 12 months. There is conflicting evidence within the published literature relating to optimal timing of palate repair. The principle applied in the UK is that of closure during the early stages of speech development.
- The most common surgical approach in cleft palate repair is the intravelar veloplasty (IVVP), in which incisions along the cleft edge provide access to the soft palate muscle. The levator muscles are dissected free (***Figure 50.8***) and sutured together in the midline to recreate a muscular sling.

Summary box 50.5

Primary surgery for cleft lip and/or palate

- Treatment staged from anterior (lip) to posterior (soft palate) in the UK
- Multiple eponymous skin incisions for lip repair but muscle reconstruction is key
- Management of the levator sling is key in cleft palate repair

Age 1–7 years: early years care/ follow-up

Following primary surgery, regular review by an MDT is essential. Many aspects of cleft care require review during the early years of childhood:

- hearing;
- speech;
- dental development;
- wound healing and aesthetics.

Hearing

Eustachian tube dysfunction plays a central role in the pathogenesis of otitis media with effusion (OME) in babies and children born with a cleft palate. Children with a cleft lip alone exhibit the same frequency of otitis media as their age-matched counterparts, whereas those children with palatal involvement may have an increased incidence of OME. Regardless of the

Bartolomeu Eustachio (Eustachius), 1513–1574, Professor of Anatomy, appointed physician to the Pope in 1547.

incidence it is important for normal speech development that hearing is within normal limits.

All children are screened at birth, but those who have a cleft palate are monitored regularly with audiological screening.

Speech

In the UK, specialist SLTs involved in cleft care engage at an early stage with families and children. Some teams will run group sessions to encourage speech development. Speech is constantly monitored during development and early intervention is advisable if speech pathology is suspected or diagnosed.

The problems that may present can be considered in two broad groups:

1. **Velopharyngeal incompetence** (VPI). Where the soft palate fails to achieve adequate velopharyngeal closure, which is required for certain sounds in speech, air escape occurs, leading to the resonance issue of hypernasality. This can lead to unintelligible speech because of either the hypernasality itself or the adaptations made by the child in an attempt to achieve velopharyngeal closure.
2. **Articulation errors**. These either arise as a compensatory mechanism, as stated above to overcome VPI, or, less commonly, are caused by jaw/dental and occlusal abnormalities.

To investigate these problems, the cleft team relies upon the specialist SLT assessment and investigations such as lateral videofluoroscopy and nasendoscopy. These investigations are used to visualise the palate as it moves in real time during speech.

Secondary speech surgery may be offered when there are structural issues to overcome such as VPI. Cleft palate repair is carried out when the palatal function is assessed to be suboptimal but other procedures that alter the dynamics of airflow during speech to reduce nasal escape may also be employed. These interventions are broadly termed pharyngoplasty procedures.

Dental

Dental anomalies are common findings in children with cleft lip and/or palate. Various phenomena, including delayed tooth development, delayed eruption of teeth and morphological abnormalities, are well documented. The number of teeth may be reduced (hypodontia) or increased (hyperdontia), occurring most commonly in the region of the cleft alveolus and involving the maxillary lateral incisor tooth. These abnormalities can occur in both primary and secondary dentition. All children with cleft lip and palate should undergo regular dental examination. Dental management should also include preventive measures such as dietary advice, fluoride supplements and fissure sealants. A well-maintained and disease-free dentition in childhood provides the optimal situation for successful orthodontic treatment.

Wound healing/aesthetics

Wound infections are rare but if they occur may lead to revision surgery. If this is a lip wound infection then revision can be timed to be pre-school or, if the problem is subtle, the lip can be revised opportunistically at the time of, for example, ABG.

Palatal dysfunction may require cleft palate repair or pharyngoplasty as described earlier in ***Speech***.

Age 7–12 years: late childhood care/follow-up

Alveolar bone grafting

ABG is a key surgical intervention for patients with alveolar involvement. The procedure can be carried out at the same time as primary cleft lip surgery and is defined as primary bone grafting. More commonly the procedure is a separate surgical intervention later in development. In this case the term secondary bone grafting is used. Secondary bone grafting is timed in relation to the development of the underlying adult dentition in the region of the cleft. Dental development can be assessed radiographically and the optimal window for bone grafting is thus easily defined. The lateral incisor tooth is commonly absent or diminutive but, if present and of normal morphology, the bone graft can be timed around the root development of this tooth (often described as early secondary grafting at age 5–7 years).

The canine tooth is most commonly used in assessment and timing. The optimal timing for intervention is at the point when the canine root is one-half to two-thirds formed (often described as late secondary grafting at age 8–11 years). As there is wide variation in the rate of dental development it is better to assess each patient and their dentition on an individual basis and tailor the treatment to this.

Patients may undergo a short period of orthodontic treatment prior to bone grafting. Less than 50% of patients with UCLP will require this. When carried out, the aim is to expand the alveolar cleft to improve surgical access. Occasionally the adjacent teeth may be aligned in advance of surgery if they are interfering with access. It is vital in a bilateral cleft to be able to stabilise the mobile anterior (premaxillary) segment to facilitate bone healing. Adjunctive secondary procedures can be carried out simultaneously, e.g. cleft lip revision.

The success rate of ABG is high. There are a variety of scoring systems used to measure outcome. Close teamwork between the cleft surgeon and the orthodontist is vital. In the situation where there is significant hypodontia in the region of the cleft a decision may be taken **not** to perform ABG. In this case the missing teeth can be replaced with a variety of restorative options, including a denture, an adhesive bridge or an implant-retained prosthesis. Bone grafting will be required for implant placement but this is better carried out when the patient is skeletally mature.

The primary objectives when performing ABG are to:

- provide adequate bony support for the adult teeth to enable subsequent orthodontic alignment;
- enable the eruption of adult teeth into the line of the dental arch;
- stabilise the premaxilla in bilateral clefts;
- definitively close the residual alveolar cleft.

The secondary objectives or associated benefits may include aesthetic improvements to the nasolabial region.

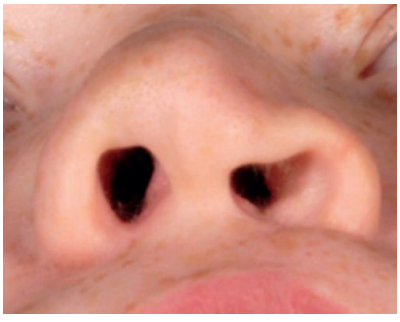

Figure 50.9 Nasal asymmetry.

Figure 50.10 Nasal asymmetry addressed by open surgical revision.

Orthodontic treatment

Children with cleft lip and alveolar involvement will often benefit from orthodontic treatment. Orthodontic treatment is commonly carried out in two phases:

1. Mixed dentition (8–10 years): to prepare the alveolar cleft for ABG (see ***Alveolar bone grafting***).
2. Permanent dentition (12–18 years): to definitively align the dental arches, aiming for a normal functioning occlusion. This phase of treatment may be linked to preparation for orthognathic surgery (jaw alignment surgery).

SECONDARY/REVISION SURGERY

These procedures are undertaken to improve aesthetics and/or function. They may be considered as procedures that were unplanned at the time of primary surgery. Specific examples are as follows.

Cleft lip/nose revision

Indications for revisional surgery to a previously repaired cleft lip are dependent on the site and severity of the residual deformity.

Relative indications for lip revision include:

- misaligned vermilion;
- lip asymmetry.

Relative indications for residual nasal deformity include:

- incorrect alar base position;
- poor nasal tip projection;
- deviation of cartilaginous nasal septum into the non-cleft nostril.

Residual nasal deformity is an external manifestation of incomplete reconstruction of the nasolabial muscle ring (see ***Clinical anatomy***). It is thought less than ideal to surgically interfere with the nasal septum in the growing child. Minor adjustments are possible before the age of 14–15 years (***Figures 50.9 and 50.10***), but more major nasal surgery is usually delayed until after this age.

Open septorhinoplasty may be considered for definitive surgical nasal correction. In patients with cleft lip and palate, open surgery is preferred to gain access to the external cartilaginous framework, which is frequently affected by the primary issues of muscle attachment related to the cleft. One common feature is collapse of the lower lateral cartilage on the cleft side together with a dislocation of the cartilaginous septum into the non-cleft nostril. The open method ensures adequate access and repositioning of the cartilaginous framework as a tertiary procedure to improve nasal tip projection, correct septal deformity and relocate alar cartilages. Grafting techniques are often employed using harvested septal (nasal) cartilage or conchal (ear) cartilage.

Orthognathic surgery

Impaired growth of the midface (maxilla) is a consequence of a number of factors, which are poorly understood. Genetic factors as well as local factors following primary surgery may be involved. Elective maxillary advancement or bimaxillary surgery may be indicated to restore aesthetics and dental occlusal harmony. Orthognathic surgery is usually performed when facial growth is complete (16–17 years in female patients, 17–19 years in male patients).

The principal dentofacial deformity associated with cleft lip and palate is underdevelopment in both the horizontal and vertical direction of the maxilla. This jaw size discrepancy can be corrected with orthognathic surgery (***Figure 50.11***).

SUMMARY

Cleft care has been the subject of significant reorganisation in recent years. Coordinated care is provided in most countries by MDTs. Specific training pathways exist in many countries for cleft surgery. Better collection and collation of outcome data will drive evidence-based improvements in care and service development.

Summary box 50.6

Summary of care for patients with cleft lip and/or palate

- Cleft surgery in infants is time sensitive
- Aesthetic and functional outcomes are important and are measured
- Surgery involves restoration of muscle position to as close to normal as possible
- Planned surgery includes bone grafting in children with alveolar involvement
- Revision/secondary surgery optimises aesthetic and functional outcomes

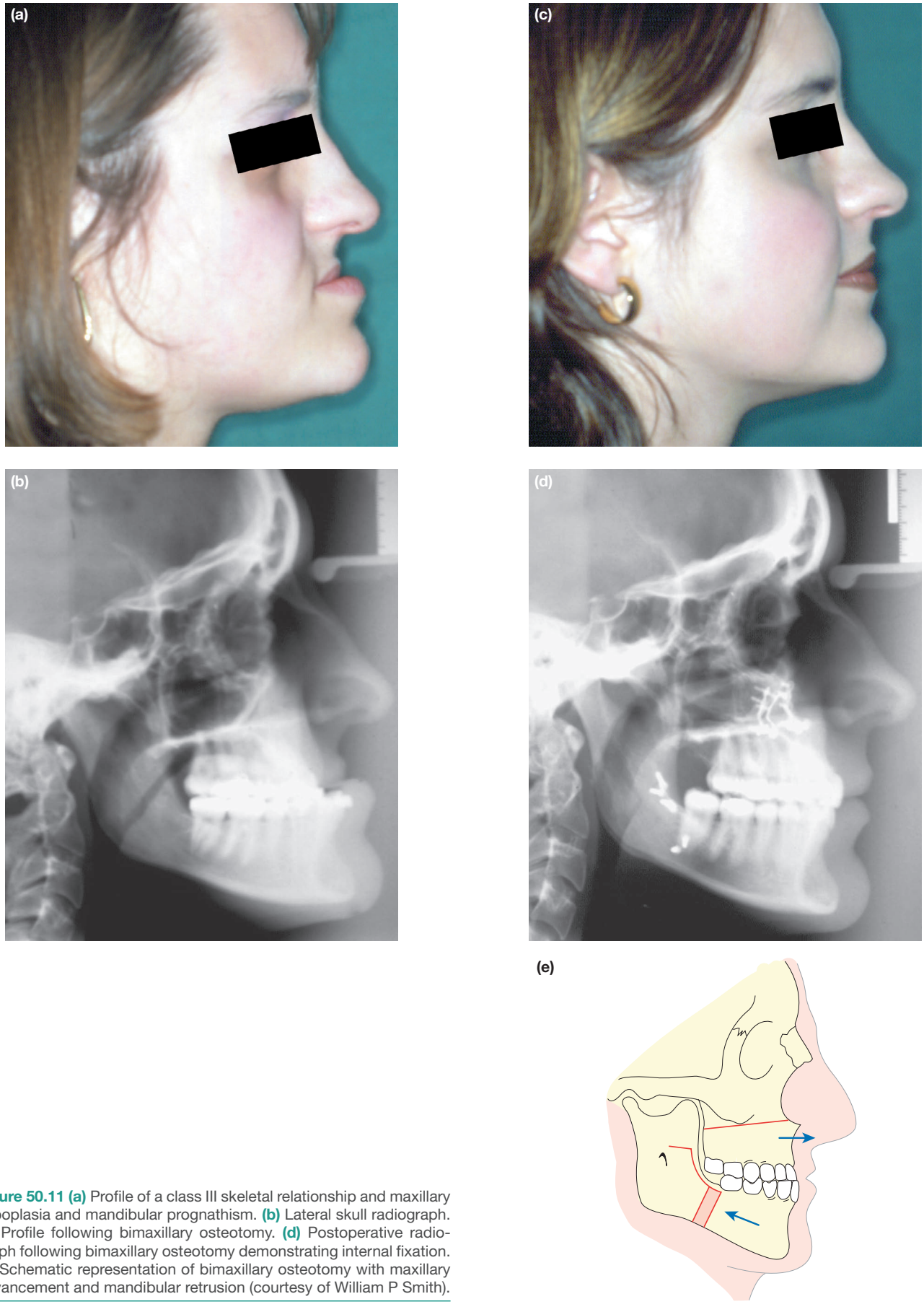

Figure 50.11 (a) Profile of a class III skeletal relationship and maxillary hypoplasia and mandibular prognathism. **(b)** Lateral skull radiograph. **(c)** Profile following bimaxillary osteotomy. **(d)** Postoperative radiograph following bimaxillary osteotomy demonstrating internal fixation. **(e)** Schematic representation of bimaxillary osteotomy with maxillary advancement and mandibular retrusion (courtesy of William P Smith).

FURTHER READING

Bearn D, Mildinhall S, Murphy T *et al.* Cleft lip and palate care in the United Kingdom – the Clinical Standards Advisory Group (CSAG) study. Part 4: outcome comparisons, training, and conclusions. *Cleft Palate Craniofac J* 2001; **38**(1): 38–43.

Bongaarts CA, Prahl-Andersen B, Bronkhorst EM *et al.* Infant orthopedics and facial growth in complete unilateral cleft lip and palate until six years of age (Dutchcleft). *Cleft Palate Craniofac J* 2009; **46**(6): 654–63.

Boorman JG, Sommerlad BC. Levator palati and palatal dimples: their anatomy, relationship and clinical significance. *Br J Plast Surg* 1985; **38**(3): 326–32.

Boorman JG, Sommerlad BC. Musculus uvulae and levator palati: their anatomical and functional relationship in velopharyngeal closure. *Br J Plast Surg* 1985; **38**(3): 333–8.

Boyne PJ, Sands NR. Secondary bone grafting of residual alveolar and palatal clefts. *J Oral Surg* 1972; **30**(2): 87–92.

Boyne PJ, Sands NR. Combined orthodontic-surgical management of residual palato-alveolar cleft defects. *Am J Orthod* 1976; **70**(1): 20–37.

Fudalej PS, Wegrodzka E, Semb G, Hortis-Dzierzbicka M. One-stage (Warsaw) and two-stage (Oslo) repair of unilateral cleft lip and palate: craniofacial outcomes. *J Craniomaxillofac Surg* 2015; **43**(7): 1224–31.

Furlow Jr LT. Cleft palate repair by double opposing Z-plasty. *Plast Reconstr Surg* 1986; **78**(6): 724–38.

Harville EW, Wilcox AJ, Lie RT *et al.* Cleft lip and palate versus cleft lip only: are they distinct defects? *Am J Epidemiol* 2005; **162**(5): 448–53.

Harville EW, Wilcox AJ, Lie RT *et al.* Epidemiology of cleft palate alone and cleft palate with accompanying defects. *Eur J Epidemiol* 2007; **22**(6): 389–95.

McBride WA, McIntyre GT, Carroll K, Mossey PA. Subphenotyping and classification of orofacial clefts: need for orofacial cleft subphenotyping calls for revised classification. *Cleft Palate Craniofac J* 2016; **53**(5): 539–49.

Naran S, Kirschner RE, Schuster L *et al.* Simonart's band: its effect on cleft classification and recommendations for standardized nomenclature. *Cleft Palate Craniofac J* 2017; **54**(6): 726–33.

Noverraz RL, Disse MA, Ongkosuwito EM *et al.* Transverse dental arch relationship at 9 and 12 years in children with unilateral cleft lip and palate treated with infant orthopedics: a randomized clinical trial (DUTCHCLEFT). *Clin Oral Investig* 2015; **19**(9): 2255–65.

Sandy J, Williams A, Mildinhall S *et al.* The Clinical Standards Advisory Group (CSAG) cleft lip and palate study. *Br J Orthod* 1998; **25**(1): 21–30.

Sandy JR, Williams AC, Bearn D *et al.* Cleft lip and palate care in the United Kingdom – the Clinical Standards Advisory Group (CSAG) study. Part 1: background and methodology. *Cleft Palate Craniofac J* 2001; **38**(1): 20–3.

Sell D, Grunwell P, Mildinhall S *et al.* Cleft lip and palate care in the United Kingdom – the Clinical Standards Advisory Group (CSAG) study. Part 3: speech outcomes. *Cleft Palate Craniofac J* 2001; **38**(1): 30–7.

Sitzman TJ, Mara CA, Long Jr RE *et al.* The Americleft Project: burden of care from secondary surgery. *Plast Reconstr Surg Glob Open* 2015; **3**(7): e442.

Sommerlad BC. Surgical management of cleft palate: a review. *J R Soc Med* 1989; **82**(11): 677–8.

Sommerlad BC. The use of the operating microscope for cleft palate repair and pharyngoplasty. *Plast Reconstr Surg* 2003; **112**(6): 1540–1.

Sommerlad BC. A technique for cleft palate repair. *Plast Reconstr Surg* 2003; **112**(6): 1542–8.

Sommerlad BC, Fenn C, Harland K *et al.* Submucous cleft palate: a grading system and review of 40 consecutive submucous cleft palate repairs. *Cleft Palate Craniofac J* 2004; **41**(2): 114–23.

Wilcox AJ, Lie RT, Solvoll K *et al.* Folic acid supplements and risk of facial clefts: national population based case-control study. *BMJ* 2007; **334**(7591): 464.

Williams AC, Bearn D, Mildinhall S *et al.* Cleft lip and palate care in the United Kingdom – the Clinical Standards Advisory Group (CSAG) study. Part 2: dentofacial outcomes and patient satisfaction. *Cleft Palate Craniofac J* 2001; **38**(1): 24–9.